



PATIENT PRESENTING CLINICAL SIGNS

PATIENT Julio Rojas History: Bleeding from the penis that was first noticed in January – diagnosed with prostatic cysts, treated and resolved with antibiotics. Reoccurred 4/28.

SPECIES Canine Physical Examination: N/A.

Urinalysis: SG 1.037, SG 7.5, 1+protein, 2+ blood. Negative bacterial growth.

BREED Mixed CBC: Normal.

Serum Biochemistry: Normal.

Radiographic Findings: N/A.

SEX

Male

ULTRASONOGRAPHIC EXAMINATION OF THE ABDOMEN

AGE

Urinary System

5 years Small urinary bladder with a normal thickness and appearance of the wall. Normal anechoic urine with no sediment or uroliths evident.

WEIGHT

17.5 #

Normal trigone area, proximal urethra, and iliac blood vessels.

Normal iliac lymph nodes. Ureters not visualized.

INTERPRETED BY

Kidneys not visualized.

Reproductive System

Prostamegaly (4.1 x 7.8 cm) with a diffuse hyperechogenic appearance and regular capsule. Focal parenchymal cyst (1.6 x 1.9 cm). Normal appearance of the peri-prostatic tissue.

Adrenal Glands

N/A.

Spleen

N/A.

Liver

N/A.

Gall bladder

N/A.

Gastrointestinal

N/A.

Pancreas

N/A.

IMAGING PERFORMED BY

Dr Megan Cassels-Conway, DVM

HOSPITAL NAME

Central Broward Animal Hospital

REFERRING VET

Dr Oms, DVM

INVOICE

304192

DATE

5/4/23



PATIENT *Free Abdomen*

Julio Rojas N/A.

SPECIES **ULTRASONOGRAPHIC FINDINGS**

Canine Primary Findings:

- BREED**
- Prostamegaly.
 - Prostatic cyst.

Mixed Secondary Findings:

- SEX**
- None.

Male

AGE **INTERPRETATION OF THE FINDINGS & FURTHER RECOMMENDATIONS**

5 years The appearance of the prostate is consistent with benign cystic prostatic hyperplasia with prostatitis an unlikely differential diagnosis.

WEIGHT At this point further assessment is not indicated.

17.5 # Specific therapy would be either castration (ideal) or use of testosterone blocking drugs.

INTERPRETED BY

Remo Lobetti, BVSc,
MMedVet (Med), PhD, Dipl.
ECVIM

IMAGING PERFORMED BY

Dr Megan Cassels-Conway,
DVM

HOSPITAL NAME

Central Broward Animal
Hospital

REFERRING VET

Dr Oms, DVM

INVOICE

304192

DATE

5/4/23



PATIENT IMAGES

Julio Rojas **Prostate**

SPECIES

Canine

BREED

Mixed

SEX

Male

AGE

5 years

WEIGHT

17.5 #

INTERPRETED BY

Remo Lobetti, BVSc,
MMedVet (Med), PhD, Dipl.
ECVIM

IMAGING PERFORMED BY

Dr Megan Cassels-Conway,
DVM

HOSPITAL NAME

Central Broward Animal
Hospital

REFERRING VET

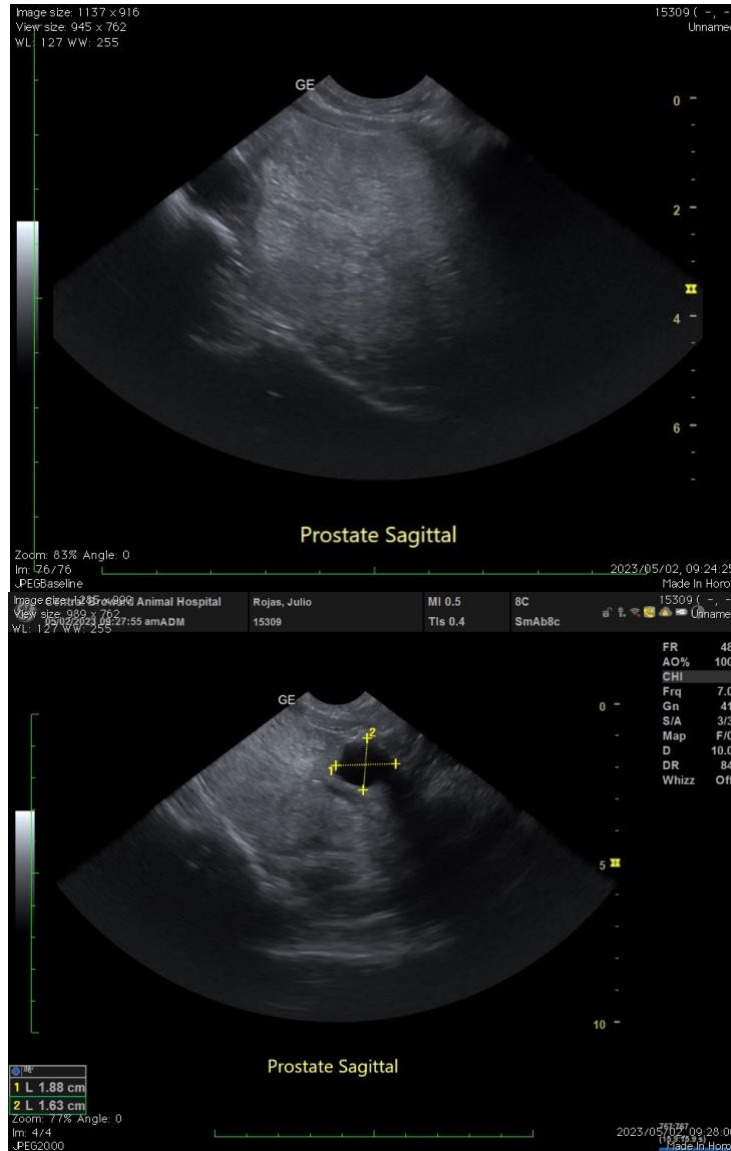
Dr Oms, DVM

INVOICE

304192

DATE

5/4/23



The information and recommendations provided are based on the images presented by the referring veterinarian. No evaluation can be communicated regarding pathology that was not visible in the image/video clips provided.

Thank you for this referral. If the clinical or image interpretation does not parallel your findings or if I can be of any further assistance, please contact me.

Remo Lobetti, BVSc, MMedVet (Med), PhD, Dipl. ECVIM (Internal Medicine)
remo.lobetti@sonopath.com